

Biochemical and Histopathological Evaluation of The Effect of Thiamine Pyrophosphate on Favipiravir-Induced Degenerative Corneal and Scleral Damage in Rats

Tiamin Pirofosfatın Sıçanlarda Favipiravir ile İndüklenen Dejeneratif Kornea ve Skleral Hasarına Etkisinin Biyokimyasal ve Histopatolojik Değerlendirmesi

Kemal Bayrakçeken¹, Hasan Akgöz², Ahmet Gökhan Ağgül³, Fikret Altındağ⁴, Halis Süleyman⁵

1 Erzincan Binali Yıldırım University, Faculty of Medicine, Department of Ophthalmology, <https://orcid.org/0000-0001-9550-1358>

2 Erzurum Regional Training and Research Hospital, Department of Ophthalmology, <https://orcid.org/0000-0003-1115-8359>

3 Agri Ibrahim Cecen University, Faculty of Pharmacy, Department of Biochemistry, <https://orcid.org/0000-0003-0377-0388>

4 Van Yuzuncu Yil University, Faculty of Medicine, Department of Histology and Embryology, <https://orcid.org/0000-0002-4074-5168>

5 Erzincan Binali Yıldırım University, Faculty of Medicine, Department of Pharmacology, <https://orcid.org/0000-0002-9239-4099>

Abstract

Introduction: Favipiravir causes ocular toxicity at high doses. Thiamine pyrophosphate (TPP) therapy can prevent ocular damage by reversing oxidative damage.

Objective: To investigate the ocular effect of favipiravir in rats and determine the protective effect of thiamine pyrophosphate (TPP) against the possible ocular toxicity of favipiravir.

Method: The rats were randomly divided into three groups; healthy control (HC), favipiravir administered (FAV), and TPP + favipiravir administered (TFAV). In the TFAV group, TPP was intraperitoneally injected at a dose of 25 mg/kg. In the HC and FAV groups, distilled water was applied as a solvent. One hour later, favipiravir was administered to the FAV and TFAV groups at 200 mg/kg orally by gavage twice a day. TPP was injected once a day. This procedure was repeated for one week. All rats were sacrificed under anesthesia, and the biochemical parameters and histopathological levels were analyzed.

Results: It was determined that the FAV group had higher blood MDA levels ($p<0.001$) and lower tGSH, SOD, and CAT levels ($p<0.001$) than the other groups. MDA levels of HC and TFAV groups were similar ($p=0.407$). It also inhibited the reduction in TPP, tGSH, SOD, and CAT ($p<0.001$). There was no significant difference between HC and TFAV groups regarding tGSH and CAT ($p>0.05$). In the histopathological examinations, severe collagen fiber degeneration and moderate hyperemia were observed in the corneal and scleral tissues in the FAV group.

Conclusion: The findings of the study showed that favipiravir caused damage to the cornea and sclera tissue through oxidative damage and TPP reduced this damage. Our study results suggest that TPP may be beneficial in Favipiravir-induced ocular toxicity.

Keywords: Favipiravir, Ocular Toxicity, Oxidative Stress, Thiamine Pyrophosphate.

Corresponding Author: Hasan Akgöz, e-mail: dr.hasanakgoz@gmail.com

Received: 21.07.2023, Accepted: 29.08.2023, Published Online: 30.09.2023

Cite: Bayrakçeken K, et al. Biochemical and Histopathological Evaluation of The Effect of Thiamine Pyrophosphate on Favipiravir-Induced Degenerative Corneal and Scleral Damage in Rats. *Acta Medica Ruha*. 2023;1(3):228-238. <https://doi.org/10.5281/zenodo.8180526>



Özet

Giriş: Favipiravir yüksek dozlarda oküler toksisiteye neden olmaktadır. Tiamin pirofosfat (TPP) tedavisi oksidatif hasarı tersine çevirerek oküler hasarı önleyebilir.

Amaç: Favipiravirin sıçanlarda oküler etkisini araştırmak ve favipiravirin olası oküler toksisitesine karşı TPP koruyucu etkisini belirlemek.

Yöntem: Sıçanlar rastgele üç gruba ayrıldı; sağlıklı kontrol (HC), favipiravir uygulanan (FAV) ve TPP + favipiravir (TFAV) uygulanan. TFAV grubuna TPP intraperitoneal olarak 25 mg/kg dozunda enjekte edildi. HC ve FAV gruplarında çözücü olarak distile su uygulandı. Bir saat sonra FAV ve TFAV gruplarına günde 2 kez 200 mg/kg oral sonda ile favipiravir uygulandı. TPP günde bir kez enjekte edildi. Bu prosedür bir hafta boyunca tekrarlandı. Tüm sıçanlar anestezi altında sakrifiye edildi ve biyokimyasal parametreler ve histopatolojik seviyeleri analiz edildi.

Bulgular: FAV grubunun diğer gruplara göre kan MDA düzeylerinin daha yüksek ($p < 0.001$), tGSH, SOD ve CAT düzeylerinin daha düşük olduğu ($p < 0.001$) belirlendi. HC ve TFAV gruplarının MDA düzeyleri benzerdi ($p = 0,407$). Ayrıca TPP, tGSH, SOD ve CAT'deki azalmayı da inhibe etti ($p < 0.001$). tGSH ve CAT açısından HC ve TFAV grupları arasında anlamlı fark yoktu ($p > 0,05$). Histopatolojik incelemelerde FAV grubunda kornea ve sklera dokularında ileri derecede kollajen lif dejenerasyonu ve orta derecede hiperemi gözlemlendi.

Sonuç: Çalışmanın bulguları, favipiravirin oksidatif hasar yoluyla kornea ve sklera dokusunda hasara neden olduğunu ve TPP'nin bu hasarı azalttığını gösterdi. Çalışma sonuçlarımız, TPP'nin favipiravirin neden olduğu oküler toksisitede faydalı olabileceğini düşündürmektedir.

Anahtar Kelimeler: Favipiravir, Oküler Toksikite, Oksidatif Stres, Tiamin Pirofosfat.

INTRODUCTION

Favipiravir is a purine nucleoside precursor antiviral drug that competitively inhibits the RNA-dependent RNA polymerase (RdRp) enzyme (1). It is converted to its active form, favipiravir-ribofuranosyl-50-triphosphate metabolite, through phosphoribosylation and phosphorylation in tissues (2). Favipiravir was first manufactured by the Japanese pharmaceutical company Fujifilm Toyama Chemical Co. Ltd. (3). It was initially found to be effective against the influenza virus in vitro (4). However, evidence from in vitro and clinical studies has shown that favipiravir is also a promising drug against a broad spectrum of RNA viruses (5). It has been determined that favipiravir is effective against many RNA viruses, such as Ebola, norovirus, and enterovirus. In addition to other RNA viruses, such as the Ebola virus, a few studies have also reported the effects of favipiravir against rhinovirus and respiratory syncytial virus (6).

It has been suggested to use high doses of favipiravir in infections of COVID-19, Ebola, and similar viruses, and it has been stated that these viruses are sensitive to high doses of favipiravir (7). However, favipiravir can have toxic effects at high doses (8), which can be seen in the form of diarrhea, nephrotoxicity, increased serum uric acid and transaminase levels, decreased white blood cell and neutrophil levels, nausea, vomiting, abdominal pain, skin rash, itching, delirium, hallucinations, and convulsions (9,10). Side effects such as blurred vision and blue light reflection have been reported after the use of favipiravir in the treatment of COVID-19 (11). Favipiravir has also been shown to cause oxidative liver damage by increasing the level of malondialdehyde (MDA) formed by peroxidation of membrane lipids and decreasing the levels of endogenous oxidants, such as catalase (CAT), superoxide dismutase (SOD) and glutathione (GSH) (12).

The global increase in cases of COVID-19 has led to the need to discover and develop new therapeutics with superior efficacy to treat this disease. Thiamine pyrophosphate (TPP) is the active metabolite of thiamine in the body. TPP participates as a cofactor in the reactions of enzymes that maintain cell redox state through the synthesis of glutathione and nicotinamide

adenine dinucleotide phosphate (NADPH) (13). It has been stated that TPP protects retinal tissue by preventing the increase in MDA from ethanol-induced oxidative damage to the retina, as well as the decrease in tGSH (14). In addition, it has been suggested that TPP suppresses the formation of diabetic retinopathy by preventing the decrease of SOD and other enzymatic antioxidant systems (15).

In the literature review, no experimental study was found regarding the effects of favipiravir on eye tissue. Therefore, in the current study, we aimed to investigate the ocular effect of favipiravir biochemically and histopathologically and determine the protective effect of TPP against the possible ocular toxicity of favipiravir.

METHOD

Animals

In the current study, 18 male albino Wistar rats (265-272 grams) were included. Animals were obtained from Experimental Animals Application and Research Center of our university. Before the experiment, the rats were kept at the appropriate temperature (21-23°C), 12 hours of light-dark cycle, and fed ad libitum. This research followed according to the Association for Research in Vision and Ophthalmology (ARVO) statement for the Use of Animals in Ophthalmic and Vision Research. This research also followed the Institute of Laboratory Animal Resources Guide for the Care and Use of Laboratory Animals. Ethical approval was obtained from the Animal Experiments Local Ethics Committee of our university for the procedures to be applied to rats (meeting date: 28.07.2022, decision no: 07/35).

Chemical Substances

Thiopental sodium was obtained from IE Ulagay (Turkey), favipiravir from a training and research hospital affiliated with the Turkish Ministry of Health, and an injectable form of TPP from Biopharma (Russia).

Experimental Groups

Healthy control (HC), favipiravir administered (FAV), and TPP + favipiravir administered (TFAV) groups were formed from rats by randomization, with six animals in each group.

Experimental Procedure

For the experiment, the animals in the TFAV (n = 6) group were injected with TPP (25 mg/kg) intraperitoneally. In the HC (n = 6) and FAV (n = 6) groups, distilled water was given. One hour after administration of TPP and distilled water, favipiravir (200 mg/kg) was given orally twice a day to rats in FAV and TFAV groups. TPP was injected once a day. This procedure was repeated for one week. At the end of a week, blood samples were taken from the tail veins of the animals for MDA, tGSH, SOD, and CAT analysis, and then euthanized with 50 mg/kg thiopental sodium, and the eyeballs were removed. The cornea, sclera, and retinal tissues of the eye were analyzed histopathologically. The obtained data were compared between the groups.

Biochemical Analyses

MDA ($\mu\text{mol/g}$ protein), GSH (nmol/g protein), and SOD (u/mg protein) in blood samples were measured using the commercial enzyme-linked immunosorbent assay (ELISA) kits for experimental animals, and each analysis was performed according to the kit instructions (product number: 706002, 703002, and 10009055, respectively, Cayman Chemical

Company). CAT (u/mg protein) determination was made according to the method proposed by Goth (16). Protein determination was undertaken spectrophotometrically at 595 nm according to the Bradford method (17).

Histopathological Examination

Eye tissues were fixed in a 10% formalin solution. After routine tissue follow-up, 5 µm sections were obtained and stained with hematoxylin-eosin. Prepared sections were analyzed histopathologically under the light microscope (Olympus BX 51, Japan). Photos were taken with a digital camera (Olympus DP 71). Histopathological findings, which were determined semi-quantitatively in the evaluation, were evaluated as absent (0), mild (1), moderate (2), and severe (3).

Statistical Analysis

IBM SPSS Statistics 22 program was used for statistical analysis and $p < 0.05$ was considered significant. The data of the study were expressed as mean value \pm standard deviation. Statistical analysis for biochemical data was performed with a one-way ANOVA test. Afterward, the Tukey HSD test was applied. Since the histopathological data were ordinal, they were preferred with the Kruskal-Wallis test, which is a non-parametric method, and then a pairwise comparison was made with Dunn's test.

RESULTS

Biochemical Results

As seen in Figure 1 and Table 1, favipiravir administration increased MDA levels compared to the HG group ($p < 0.001$). The addition of TPP to favipiravir appeared to inhibit this increase ($p < 0.001$) and approximate the MDA data of the TFAV group to those of healthy animals ($p = 0.407$). tGSH, SOD, and CAT levels obtained from animals in the FAV group were found to be statistically significantly lower than those of the HC and TFAV groups ($p < 0.001$). With TPP application, tGSH and CAT levels were close to healthy animals ($p > 0.05$), while the difference in SOD levels was significant ($p = 0.003$).

Table 1. Analysis Results of Biochemical Variables

Variables	HC	FAV	TFAV	HC vs. FAV	HC vs. TFAV	FAV vs. TFAV	F/p
	X \pm SD (mean \pm standard deviation)			p values			
MDA	1.13 \pm 0.13	4.60 \pm 0.37	1.33 \pm 0.26	<0.001	0.407	<0.001	304.658/<0.001
tGSH	3.56 \pm 0.13	1.58 \pm 0.17	3.27 \pm 0.26	<0.001	0.050	<0.001	182.645/<0.001
SOD	8.65 \pm 0.25	4.20 \pm 0.57	7.69 \pm 0.35	<0.001	0.003	<0.001	192.009/<0.001
CAT	6.36 \pm 0.11	3.50 \pm 0.21	5.98 \pm 0.41	<0.001	0.066	<0.001	192.696/<0.001

HC: Healthy Control; FAV: Favipiravir Group; TFAV: Thiamine Pyrophosphate+Favipiravir Group; MDA: Malondialdehyde; tGSH: Total Glutathione; SOD: Superoxide Dismutase; CAT: Catalase.

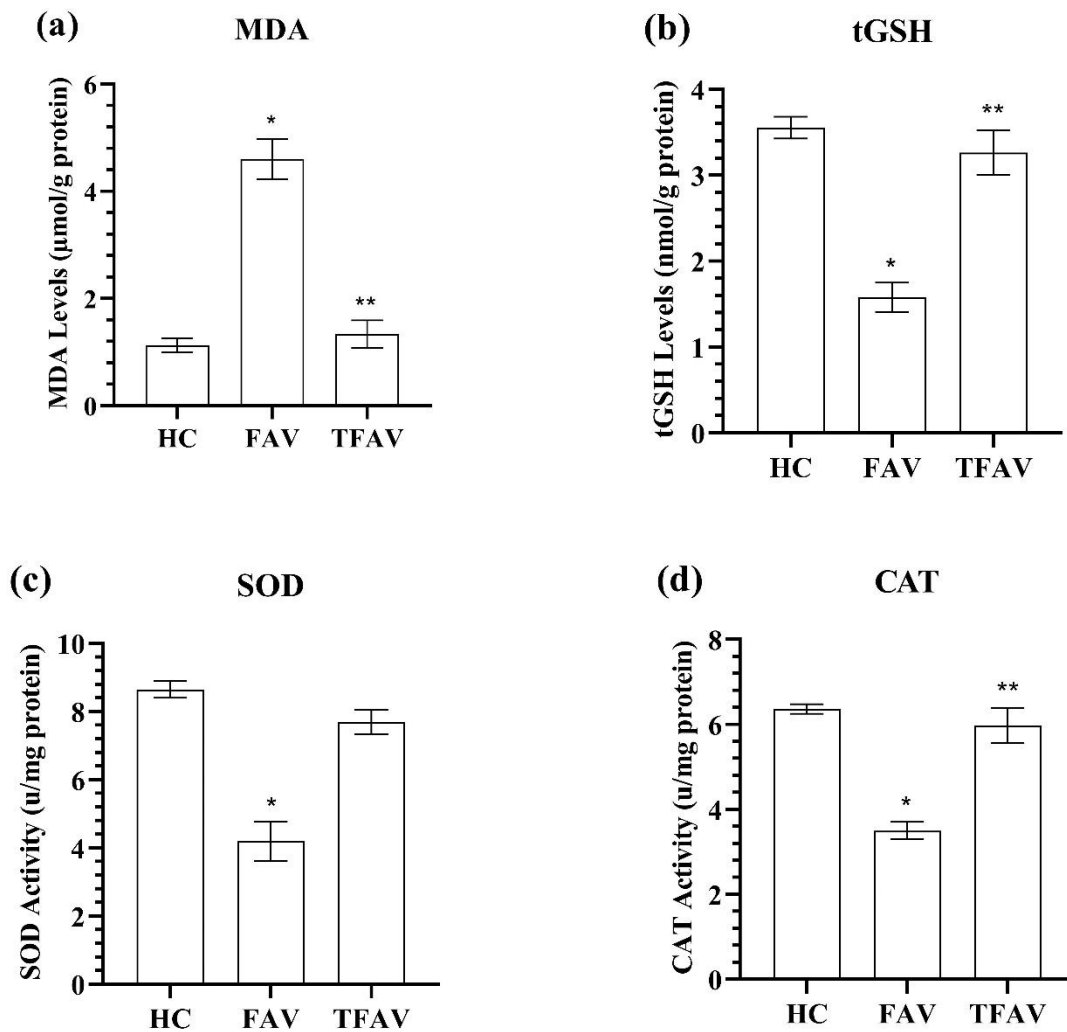


Figure 1. MDA, tGSH, SOD, and CAT values of eyes samples taken from study groups. Bars are mean±SD, n=6. (a), MDA levels; (b), tGSH levels; (c), SOD activity; (d), CAT activity. * means $p < 0.001$ compared to HC and TFAV groups; ** means $p > 0.05$ compared to HC group. HC: Healthy Control; FAV: Favipiravir Group; TFAV: Thiamine Pyrophosphate+Favipiravir Group; MDA: Malondialdehyde; tGSH: Total Glutathione; SOD: Superoxide Dismutase; CAT: Catalase.

Histopathological Results

The histopathological analysis results of the groups are summarized in Table 2.

Table 2. Analysis Results of Scoring.Histopathological

Variables	HC	FAV	TFAV	HC vs. FAV	HC vs. TFAV	FAV vs. TFAV	KW/p	
	X ±SD (mean±standard deviation)			p values				
Cornea	Degeneration	0	2.67±0.52	1.00±0.63	<0.001	0.240	0.110	14.775/0.001
	Hyperemia	0	0	0	-	-	-	-
Sclera	Degeneration	0	2.83±0.41	0.83±0.41	<0.001	0.262	0.079	15.540/0.001
	Hyperemia	0	2.17±0.41	0	<0.001	1.000	<0.001	16.615/0.001
Retina	Degeneration	0	0	0	-	-	-	-
	Hyperemia	0	0	0	-	-	-	-

HC: Healthy Control; FAV: Favipiravir Group; TFAV: Thiamine Pyrophosphate+Favipiravir Group.

No pathological findings were found in the corneal, scleral, and retinal tissues of the animals in the HC group (Figure 2a-c).

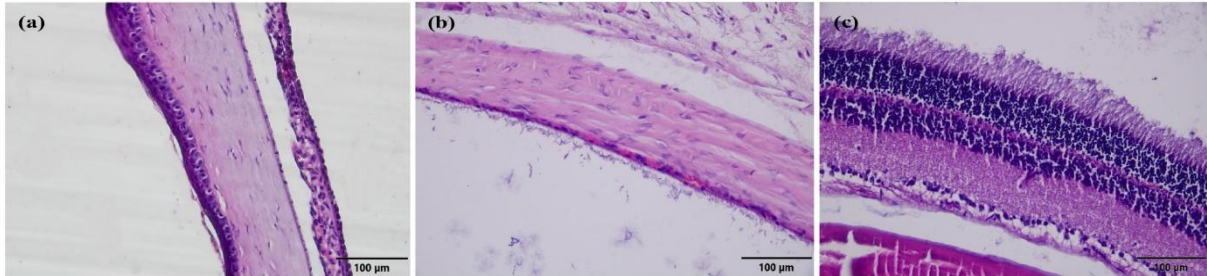


Figure 2. Histopathological appearance of the HC group (HxE). a- Normal appearance of the corneal tissue. b- Normal appearance of scleral tissue. c- Normal appearance of retinal tissue. HC: Healthy Control; FAV: Favipiravir Group; TFAV: Thiamine Pyrophosphate+Favipiravir Group.

However, severe collagen fiber degeneration was observed in the corneal and scleral tissue of the FAV group (Figure 3a,b). In addition, favipiravir was found to cause moderate hyperemia in the scleral tissue (Figure 3b). Microscopic pathological findings were not present in the retinal tissue of the animals treated with favipiravir (Figure 3c).

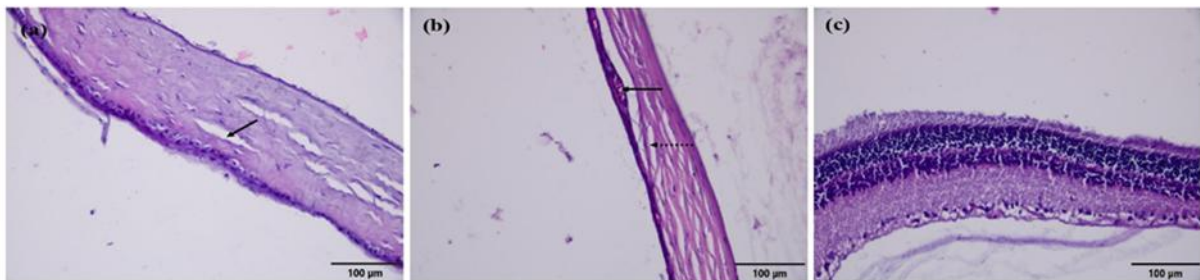


Figure 3. Histopathological appearance of the FAV group (HxE). a- Severe collagen fiber degeneration (arrow) and decrease in collagen fiber density in the corneal tissue. b- Severe collagen fiber degeneration (arrow) and moderate hyperemia (dashed arrow) in scleral tissue. c- Normal appearance of retinal tissue. HC: Healthy Control; FAV: Favipiravir Group; TFAV: Thiamine Pyrophosphate+Favipiravir Group.

There was mild collagen fiber degeneration in the cornea and sclera tissue of the animals in the TFAV group. No hyperemia was observed in the cornea and sclera tissues. (Figure 4a, b). In addition, the retinal tissue of the TFAV group had a normal histological appearance (Figure 4c).

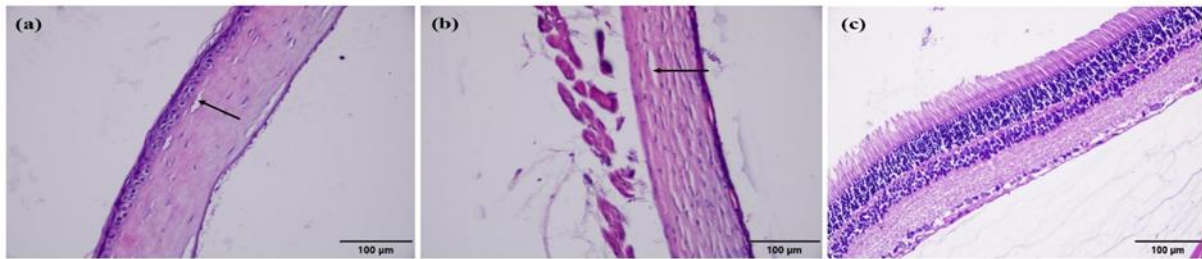


Figure 4. Histopathological appearance of the TFAV group (HxE). a- Mild collagen fiber degeneration (arrow) finding in the corneal tissue. b- Mild collagen fiber degeneration (arrow) in scleral tissue. c- Normal appearance of retinal tissue. HC: Healthy Control; FAV: Favipiravir Group; TFAV: Thiamine Pyrophosphate+Favipiravir Group.

DISCUSSION

In the current study, the effect of TPP on favipiravir-induced oxidative corneal and scleral damage was investigated biochemically and histopathologically. Our biochemical findings showed that favipiravir significantly increased the amount of MDA, whereas it significantly decreased the levels of endogenous antioxidants, namely tGSH, SOD, and CAT.

The main reason why we measured the MDA level to evaluate ocular damage caused by favipiravir is that MDA is one of the most important indicators of lipid peroxidation (LPO). Many studies have reported that in damaged corneal and scleral tissues, there is an increase in the level of reactive oxygen radicals (ROS) and oxidative stress products, such as MDA (18,19). MDA plays a role in the continuation of oxidative cell damage after LPO (20). MDA also exerts its toxic effect by causing the cross-linking of cell membrane components and inactivating receptors and enzymes in membranes (21). However, to our knowledge, in the literature, there is no experimental study that has investigated the toxic effect of favipiravir on ocular tissue. However, Kara et al. reported that favipiravir triggered oxidative damage by causing an increase in MDA levels in liver and kidney tissues (12). Analysis results of the current study and literature information suggest that as a result of favipiravir administration, the prooxidant/antioxidant balance shifts in favor of prooxidants in various tissues.

Recent experimental studies have shown that the toxic effects of various drugs can be reduced by treatment with substances and antioxidants that prevent the formation of ROS (22,23). Therefore, in our study, we investigated the effect of TPP, which is known to have antioxidant properties, against possible favipiravir-related ocular toxicity. TPP is a cofactor of enzymes that play a role in maintaining the cellular redox state by synthesizing NADPH and GSH and showing antioxidant properties (13). The findings obtained from the current study revealed that the administration of TPP to the rats significantly reduced the increase in MDA caused by favipiravir. The role of TPP therapy has been previously investigated in certain ocular diseases, and related data support our findings. Çinici et al. determined that TPP exhibited a protective effect by inhibiting MDA in ethambutol-induced ocular toxicity (14). Similarly, in another study, it was reported that the increase in the amount of MDA in the retinal tissues of rats associated with hyperglycemia was significantly inhibited by TPP administration (15). Our experimental results and information obtained from previous studies show that TPP

protects ocular tissue from the toxic effect of favipiravir by creating an antioxidant effect on ROS.

The impairment of the oxidant/antioxidant balance and oxidative stress damage is among the most implicated mechanisms in the etiopathogenesis of ocular toxicity caused by various drugs (23,24). Therefore, in our study, we measured tGSH levels in blood samples taken from the rats to evaluate favipiravir-induced oxidative damage. GSH is one of the important indicators of antioxidant capacity and is known to protect tissues against oxidative stress (25). It is one of the most well-known important antioxidants in living tissues. GSH, catalyzed by active glutathione peroxidase, reacts with hydrogen peroxide and organic peroxides to detoxify and protect cells from ROS damage (26). Although there are many studies documenting a decrease in the amount of GSH in the presence of oxidative damage in ocular tissue (23,24), there is no study in the literature that associates favipiravir-induced ocular damage with decreased GSH. The decrease in the amount of endogenous tGSH in serum samples of rats administered favipiravir in the current study supports the literature.

Other enzymatic antioxidants that were observed to be decreased in the serum samples of the rats as a result of favipiravir administration were SOD and CAT. SOD catalyzes the conversion of superoxide to hydrogen peroxide and molecular oxygen, thereby inhibiting LPO (27). As a result of this reaction, hydrogen peroxide is formed, which is detoxified by the CAT enzyme (28). Therefore, in our study, we decided to examine the SOD enzyme together with the CAT enzyme to prevent the destructive effect of ROS. Although it has been reported in the literature that a decrease in enzyme activities, such as SOD and CAT is associated with ocular oxidative damage (14,15,22,29), no study has associated favipiravir-induced ocular damage with endogenous antioxidant enzyme activities. However, it is known that xanthine oxidase, which is formed as a result of the metabolism of favipiravir, is a major source of free radicals, and there are many studies documenting that xanthine oxidase causes ROS production, which then results in a decrease in antioxidants in tissues (12,30). In a recent study, it was reported that following favipiravir administration, there was a decrease in SOD, CAT, GSH, and glutathione peroxidase levels, as well as an increase in MDA levels in liver and kidney tissues (12). All these literature data support our findings.

In this study, it was observed that TPP inhibited the decrease in tGSH, SOD, and CAT levels along with the increase in favipiravir-related MDA. As our experimental results revealed, the oxidant-antioxidant balance was impaired in the FAV group and oxidants became dominant, but this balance was maintained in the group that was additionally administered TPP. In the current literature, there are limited studies on the effect of TPP on oxidative stress in ocular tissue (14,15). It has been reported that TPP protects ocular tissue against oxidative damage induced by ethambutol and hyperglycemia (14,16). Our findings are consistent with previous reporting the antioxidant effect of TPP.

The biochemical findings of our study were supported by histological findings. The results of our histological findings showed that the FAV group had severe collagen fiber degeneration in the corneal and scleral tissues and moderate hyperemia in the scleral tissue. We consider that this histopathological damage associated with favipiravir is related to the increase in oxidant parameters. These findings are in line with the case report of Doran et al., who observed blurred vision and blue light reflection after favipiravir treatment in COVID-19 cases (11). However, in our study, treatment with TPP significantly suppressed favipiravir-induced corneal and scleral degeneration and hyperemia. These findings are also consistent with previous studies reporting that TPP prevented ocular toxicity caused by ethambutol and retinopathy damage caused by hyperglycemia (14,15).

CONCLUSION

In this study, favipiravir caused an increase in oxidants and a decrease in antioxidants in blood serum, and TPP significantly inhibited the favipiravir-related oxidant increase and antioxidant decrease. Our histopathological findings revealed that the retinal tissue was not affected by favipiravir, but significant histopathological damage developed in the corneal and scleral tissues of the rats. TPP alleviated favipiravir-related corneal and scleral damage. To our knowledge, this is the first study to show that favipiravir-induced ocular toxicity is associated with increased oxidative damage in a rat model. Furthermore, treatment with TPP was determined to reverse this oxidative damage and prevent ocular damage. Our experimental results suggest that TPP may be useful in the treatment of favipiravir-related ocular damage. Further studies are needed to elucidate the mechanisms through which TPP acts. It is important to directly measure and evaluate oxidant and antioxidant parameters in corneal, scleral, and retina tissues.

Funding: There is no specific funding related to this research.

Conflict of interest: The authors received no financial support for the research, authorship, and/or publication of this article.

REFERENCES

1. Łagocka R, Dzieziejko V, Kłos P, Pawlik A. Favipiravir in therapy of viral infections. *Journal of Clinical Medicine*. 2021;10(2):273. <https://doi.org/10.3390/jcm10020273>
2. Furuta Y, Gowen BB, Takahashi K, Shiraki K, Smee DF, Barnard DL. Favipiravir (T-705), a novel viral RNA polymerase inhibitor. *Antiviral Research*. 2013;100(2):446-54. <https://doi.org/10.1016/j.antiviral.2013.09.015>
3. McCreary EK, Pogue JM. Coronavirus disease 2019 treatment: a review of early and emerging options. *Open Forum Infectious Diseases*. 2020;7(4):ofaa105. <https://doi.org/10.1093/ofid/ofaa105>
4. Hashemian SM, Farhadi T, Velayati AA. A review on favipiravir: the properties, function, and usefulness to treat COVID-19. *Expert Review of Anti-infective Therapy*. 2021;19(8):1029-1037. <https://doi.org/10.1080/14787210.2021.1866545>
5. Delang L, Abdelnabi R, Neyts J. Favipiravir as a potential countermeasure against neglected and emerging RNA viruses. *Antiviral Research* 2018;153:85-94. <https://doi.org/10.1016/j.antiviral.2018.03.003>
6. Shiraki K, Daikoku T. Favipiravir, an anti-influenza drug against life-threatening RNA virus infections. *Pharmacology & Therapeutics*. 2020;209:107512. <https://doi.org/10.1016/j.pharmthera.2020.107512>
7. Beigel JH, Tomashek KM, Dodd LE, et al. Remdesivir for the treatment of Covid-19 - final report. *New England Journal of Medicine*. 2020;383(19):1813-1826. <https://doi.org/10.1056/NEJMoa2007764>
8. Pilkington V, Pepperrell T, Hill A. A review of the safety of favipiravir - a potential treatment in the COVID-19 pandemic? *Journal of Virus Eradication*. 2020;6(2):45-51. [https://doi.org/10.1016/S2055-6640\(20\)30016-9](https://doi.org/10.1016/S2055-6640(20)30016-9)
9. Chen C, Zhang Y, Huang J, et al. Favipiravir versus arbidol for clinical recovery rate in moderate and severe adult COVID-19 patients: A prospective, multicenter, open-label, randomized controlled clinical trial. *Frontiers of Pharmacology*. 2021;12:683296. <https://doi.org/10.3389/fphar.2021.683296>
10. Doğan E, Çeviker S, Vurucu S, et al. Investigation of the frequency of adverse effects in patients treated with favipiravir as SARS-CoV-2 treatment. *Klimik Journal*. 2021;34(2):95-98. <https://doi.org/10.36519/kd.2021.3563>
11. Doran MA, Aytogan H, Ayıntap E. Fluorescence of ocular surface in a Covid -19 patient after favipiravir treatment: a case report. *Virology Journal*. 2021;18(1):146. <https://doi.org/10.1186/s12985-021-01610-3>

12. Kara A, Yakut S, Caglayan C, Atçalı T, Ulucan A, Kandemir FM. Evaluation of the toxicological effects of favipiravir (T-705) on liver and kidney in rats: biochemical and histopathological approach. *Drug and Chemical Toxicology*. 2023;46(3):546-556. <https://doi.org/10.1080/01480545.2022.2066116>
13. Gangolf M, Czerniecki J, Radermecker M, et al. Thiamine status in humans and content of phosphorylated thiamine derivatives in biopsies and cultured cells. *Plos One*. 2010;5(10):e13616. <https://doi.org/10.1371/journal.pone.0013616>
14. Cinici E, Cetin N, Ahiskali I, et al. The effect of thiamine pyrophosphate on ethambutol-induced ocular toxicity. *Cutaneous and Ocular Toxicology*. 2016;35(3):222-227. <https://doi.org/10.3109/15569527.2015.1077857>
15. Cinici E, Ahiskali I, Cetin N, et al. Effect of thiamine pyrophosphate on retinopathy induced by hyperglycemia in rats: A biochemical and pathological evaluation. *Indian Journal of Ophthalmology*. 2016;64(6):434-439. <https://doi.org/10.4103/0301-4738.187666>
16. Góth L. A simple method for determination of serum catalase activity and revision of reference range. *Clinica Chimica Acta*. 1991;196(2-3):143-151. [https://doi.org/10.1016/0009-8981\(91\)90067-m](https://doi.org/10.1016/0009-8981(91)90067-m)
17. Bradford MM. A rapid and sensitive method for the quantitation of microgram quantities of protein utilizing the principle of protein-dye binding. *Analytical Biochemistry*. 1976;72:248-254. <https://doi.org/10.1006/abio.1976.9999>
18. Zi Y, Deng Y, Zhao J, et al. Morphologic and biochemical changes in the retina and sclera induced by form deprivation high myopia in guinea pigs. *BMC Ophthalmology*. 2020;20(1):105. <https://doi.org/10.1186/s12886-020-01377-1>
19. Suresh PK, Sah AK, Daharwal SJ. Role of free radicals in ocular diseases: An overview. *Research Journal of Pharmacy and Technology*. 2014;7(11):1330-1344.
20. Nita M, Grzybowski A. The role of the reactive oxygen species and oxidative stress in the pathomechanism of the age-related ocular diseases and other pathologies of the anterior and posterior eye segments in adults. *Oxidative Medicine and Cellular Longevity*. 2016;2016:3164734. <https://doi.org/10.1155/2016/3164734>
21. Ayala A, Muñoz MF, Argüelles S. Lipid peroxidation: production, metabolism, and signaling mechanisms of malondialdehyde and 4-hydroxy-2-nonenal. *Oxidative Medicine and Longevity*. 2014;2014:360438. <https://doi.org/10.1155/2014/360438>
22. Sunar M, Yazici GN, Mammadov R, Kurt N, Arslan YK, Süleyman H. Coenzyme Q10 effect on cisplatin-induced oxidative retinal injury in rats. *Cutaneous and Ocular Toxicology*. 2021;40(4):312-318. <https://doi.org/10.1080/15569527.2021.1949336>
23. Karakurt Y, Süleyman H, Keskin Cimen F, et al. The effects of lutein on optic nerve injury induced by ethambutol and isoniazid: an experimental study. *Cutaneous and Ocular Toxicology*. 2019;38(2):136-140. <https://doi.org/10.1080/15569527.2018.1539010>
24. Icel E, Uçak T, Agcayazi B, et al. Effects of Pycnogenol on cisplatin-induced optic nerve injury: an experimental study. *Cutaneous and Ocular Toxicology*. 2018;37(4):396-400. <https://doi.org/10.1080/15569527.2018.1495224>
25. Goc Z, Szaroma W, Kapusta E, Dziubek K. Protective effects of melatonin on the activity of SOD, CAT, GSH-Px and GSH content in organs of mice after administration of SNP. *The Chinese Journal of Physiology*. 2017;60 (1):1-10. <https://doi.org/10.4077/CJP.2017.BAF435>
26. Forman HJ, Zhang H, Rinna A. Glutathione: overview of its protective roles, measurement, and biosynthesis. *Molecular Aspects of Medicine*. 2009;30(1-2):1-12. <https://doi.org/10.1016/j.mam.2008.08.006>
27. Kurutas EB. The importance of antioxidants which play the role in cellular response against oxidative/nitrosative stress: current state. *Nutrition Journal*. 2016;15(1):71. <https://doi.org/10.1186/s12937-016-0186-5>

- 28.** Ighodaro O, Akinloye O. First line defence antioxidants-superoxide dismutase (SOD), catalase (CAT) and glutathione peroxidase (GPX): Their fundamental role in the entire antioxidant defence grid. *Alexandria Journal of Medicine*. 2018;54(4):287-293. <https://doi.org/10.1016/j.ajme.2017.09.001>
- 29.** Yazici GN, Sunar M, Süleyman B, Abdülkadir Çoban T, Kemal Arslan Y, Süleyman H. Effect of pycnogenol on ethanol-related oxidative retinal injury: an experimental study. *European Review for Medical and Pharmacological Sciences*. 2022;26(14):5225-5232. https://doi.org/10.26355/eurrev_202207_29312
- 30.** Desco MC, Asensi M, Márquez R, et al. Xanthine oxidase is involved in free radical production in type 1 diabetes: protection by allopurinol. *Diabetes*. 2002;51(4):1118-1124. <https://doi.org/10.2337/diabetes.51.4.1118>